



**About the author:**  
Lambert J. Stumpel, III, DDS  
Private Practice  
San Francisco, California

# Model-Based Guided Implant Surgery; Planned Precision

Lambert J. Stumpel, III, DDS

Creating an osteotomy in bone is a relatively easy clinical procedure compared to many of the common dental procedures performed in dental practice; however, clinically, creating the osteotomy in the correct position is difficult and creating it in the wrong location can even be dangerous. Because of this only a small fraction of dentists place dental implants. In one American Dental Association report<sup>1</sup> the estimation was made that only 11% of dentists in the United States place dental implants. That number might have increased over the last several years, but it is indicative of the hesitation found within the profession. Analyzing the situation, one could wish for a way that the clinician is virtually guaranteed that the implant will end up exactly in the planned position, improving the prosthetic reliability and eliminating the possibility of encroaching on critical structures. The only surgical skill a clinician would need to acquire would be what is needed for actual drilling and placement. That time has come. Guided implant surgery is a paradigm shift that will allow a greater number of dentists to place implants expertly and expose a much greater number of patients

to this type of treatment modality.

The position of an implant is comparable to the position of an object in space, as defined by its x, y, and z coordinates. In dentistry, the x-plane is known as the mesio-distal plane; the y-plane is buccolingual; and the z-axis defines the length of the implant relative to the depth of the implant platform to the osseous crest. There are specific boundaries within which dentists should stay, including neighboring teeth; critical structures such as nerves and sinuses; and, of course, the available bony volume. Staying within these boundaries will place an implant in bone without problems, but does not address the only reason implants are placed: to function as a foundation of a prosthetic reconstruction. Hence, the final prosthetic outcome has to be factored in to plan for the placement of a successful dental implant.

Surgical guides that communicate prosthetic reconstructive requirements in relation to the available bone volume come in many shapes and forms; from very simplistic and non-limiting, to partially limiting and fully limiting.<sup>2-9</sup> The non-limiting design mostly communicates the desired prosthetic crown

*“Guided implant surgery is a paradigm shift that will allow [more] dentists to place implants expertly...”*



Figure 1: PVS putty impression with paper staple in estimated mesio-distal axis.

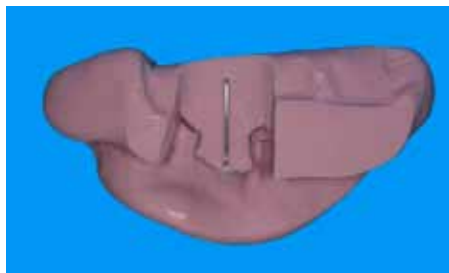


Figure 3: The staple has been repositioned based on modification data derived from the radiograph.

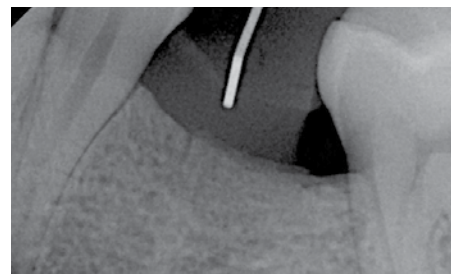


Figure 2: Radiograph depicting the trajectory encroaching on the premolar root.

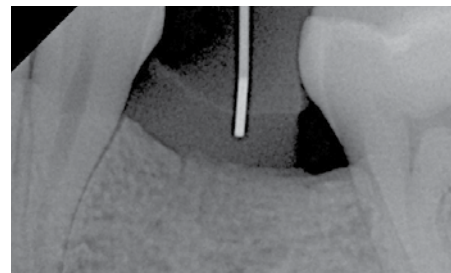
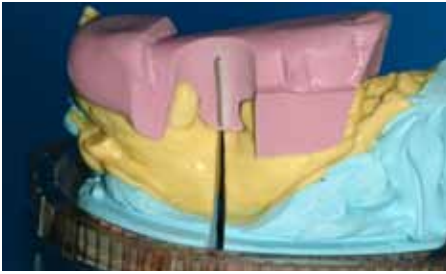


Figure 4: Radiograph confirming the correct trajectory.



**Figure 5:** Approved mesio-distal trajectory is duplicated to the cutting plane of the cast.



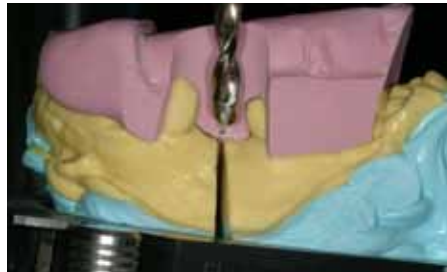
**Figure 6:** The desired bucco-lingual implant position is transcribed to the cast, as well as the position of the implant platform.



**Figure 7:** The surveyor table is programmed with the approved mesio-distal plane.



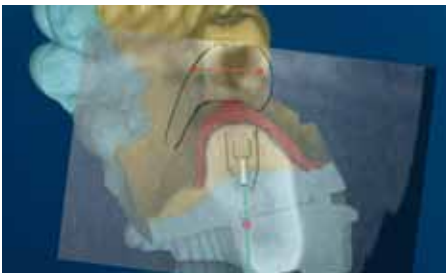**Figure 8:** Subsequently, the bucco-lingual trajectory is copied to the surveyor table position.



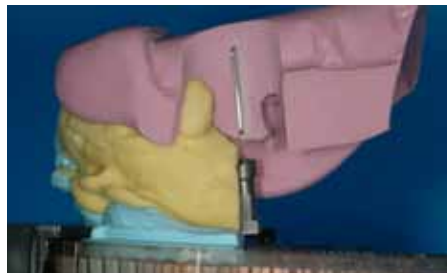**Figure 9:** Once the cast has been reassembled, the mesio-distal plane is again confirmed.



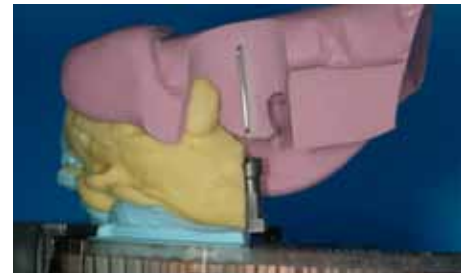**Figure 10:** Placement of the laboratory analog after the cast osteotomy, with the implant platform at the previously marked position.



**Figure 11:** Superposition of CT-derived planning data onto a cast depicting the extent of information available with model-based planning.



**Figure 12:** The mesio-distal position of the laboratory analog is confirmed to coincide with the radiographic marker.



**Figure 13:** Preoperative radiograph confirming the correctness of the trajectory of the guide sleeve in the surgical guide.

contours in relation to the implant site; an example is a vacuform guide. A partially limiting design adds to that a guide sleeve indicating the direction of the initial twist drill. A fully limiting design will have the option to guide all drills and the implant during placement. As the design becomes more restrictive, the encoded information within the guide increases. An experienced surgeon can be aided by the less limiting guides and will be able to place an implant correctly. During surgery a series of radiographs will often be taken to confirm the correct path of the developing osteotomy, and most often a flap will have to be raised to appreciate the available bone volume. A fully limiting surgical guide will have the information that otherwise would be acquired during surgery preprogrammed into its design. Therefore, during surgery there will be no decisions made as to the path of the osteotomy because these decisions will have

been previously made, with the prosthetic work-up leading to the formation of the fully limiting guide. With the fully limiting design, the final position of the implant is known before the actual surgery; therefore, the concurrent prosthetic phase can be initiated. Provisional crowns and definitive abutments can be generated before the surgery. There are reports suggesting that if the final abutment is delivered at the time of surgery and not replaced afterwards, this might lessen the change of resorptive bone remodeling.<sup>10</sup>

Fully preplanning implant placement is quite a conceptual shift from how implants have been placed historically and will require a different presurgical planning approach. The acquiring technologies available can be divided into digital, analog, or a combination of both. Examples of fully digital computer-based planning and subsequent surgical guide fabrication are

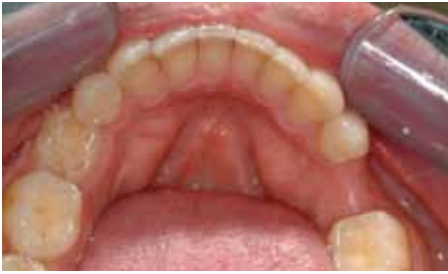Nobel Guide™ (Nobel Biocare, Yorba Linda, CA), SurgiGuide (Materialise Dental Inc, Glen Burnie, MD), and iGuide (Ident Imaging Inc, Ft. Lauderdale, FL). A combination digital/analog can be found in Implant Location System (Tactile Technologies Inc, Rehovot, Israel).

This article will describe a method known as model-based, planned guided implant surgery. It will use a series of conventional analog techniques to develop a fully limiting surgical guide, allowing for minimally invasive implant placement, and when appropriate, followed by immediate load prosthesis.

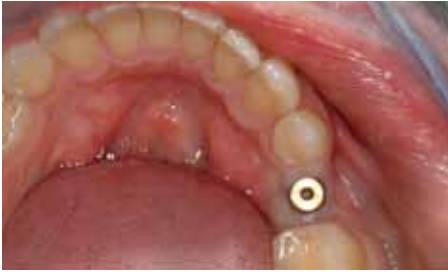## DATA ACQUISITION

As previously mentioned, there are three planes that must be considered. The x plane, concurrent with the mesio-distal plane, can be evaluated on radiographs, as can the z axis. The y plane must be studied by sounding the bone.






**Figure 14:** The intraoral condition, depicting the missing premolar.



**Figure 16:** Clinical situation 5 minutes after the start of surgery.

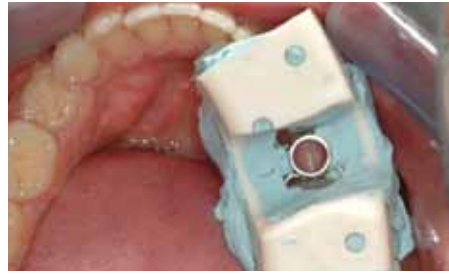

**Figure 18:** The H-frame with incorporated guided sleeve.

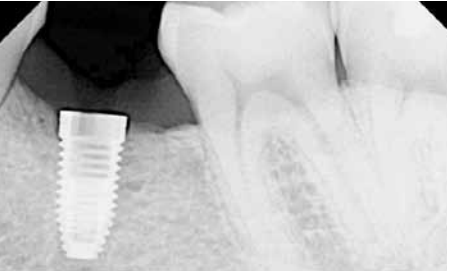Bone sounding has been used for many years in dentistry to develop an understanding of bone volume.<sup>11-18</sup> By measuring the thickness of the overlying gingival tissue at consecutive sites encompassing the ridge, this information can be used to subtract said measurements from a cast depicting the proposed implant site. This can be an edentulous site or a dentulous site if the tooth still needs to be extracted. The resulting remaining volume is an indication of the available bone volume. The results obtained via this technique are quite reliable as indicated by work from Perez et al.<sup>19</sup>

The mesio-distal plane is mostly limited by the neighboring teeth and the requirements for the prosthetic reconstruction. It is helpful to have a technique available that will allow for evaluation of the proposed mesio-distal inclination and then make controlled corrections to the initial path.

To do this, first take a preoperative polyvinyl siloxane (PVS) putty impression. Then cut the impression to expose the site of the proposed prosthetic reconstruction



**Figure 15:** The PVS surgical stent in position to start guided implant placement.



**Figure 17:** Postoperative radiograph, depicting implant placement consistent with preoperative planning.

at the mid-crestal level. It will expose the interproximal surface of the neighboring teeth and the top of the edentulous crest. Place a paper staple in the estimated axis of the planned implant (Figure 1). Place the assembly intraorally and expose a radiograph. On the radiograph it is now possible to extend the metal from the staple to the underlying osseous structure (Figure 2). The path can now be evaluated, and rotational and translational improvements can be measured.

The staple is then removed from the putty. It will have left small indentations, so it will be possible to make needed adjustments relative to the original position as determined by the radiograph. Reposition the staple (Figure 3), place the assembly back into the mouth and take another radiograph to confirm that the staple is now in the desired mesio-distal position (Figure 4). The assembly will be used to transfer the mesio-distal position to the cast.

The z axis is defined by the length of the implant and the relative position of the top of the implant platform. The length can be derived from the radiograph, and is most often limited by anatomic structures, such as the mandibular nerve and the maxillary sinus. The top of the implant can be placed supra-, equi-, or subcrestally, depending on operator preference.

The remaining plane is the bucco-lingual or y plane. To determine this plane, take a short dental needle and place an endodontic rubber stop at its apex. Perforate the

soft tissue and measure the displacement of the stop relative to the apex of the needle. The resulting measurement indicates the thickness of the overlying tissue. The measurements are made at a minimum of five sites. The first site is the most clinically accessible apical area on the buccal. The site should be recorded. The next site is on the buccal just below the junction with the crest and the buccal. The measurements are repeated on the same sites on the lingual. Lastly, the mid-crest is measured, although often this measurement can also be derived from the radiograph. Alternatively, more sites can be measured to get a more complete data set but, in the author's opinion, if the narrowest dimensions are measured then the maximum available bone volume will be known, with the knowledge that more bone is available laterally from the measured axis.

## THE TRANSFER CAST

Because the cast is used to derive the available bone volume in the bucco-lingual plane, it is of the utmost importance that the crest and the soft tissue overlying it are correctly duplicated. Hence, the soft tissue should tightly adapt to the bone; care has to be exercised to not "pull" the tissue away from the bone because this would inflate the available bone volume. Critical sites are the buccal fold and the mandibular lingual concavity. In addition, the maximum amount of the crest should be captured. Therefore, an impression tray is extended around the proposed implant site with orthodontic tray wax, to improve the adaptation and maximize the captured crest height. A non-reversible hydrocolloid can be used to capture the impression (Cavex Color Change, Cavex Holland BV, Haarlem, The Netherlands).

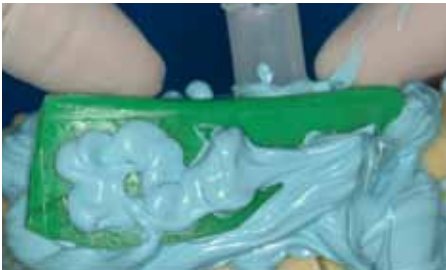An impression historically is cast in dental stone and this is certainly an option. The author proposes that the impression be cast in a dedicated casting PVS material (Mach-Slo™/Blu-Mousse®, Parkell Inc, Edgewood, NY). Although a less economical casting material per volume unit, it is very easy to use in the dental office and during the remainder of the laboratory phase. Because the cast has to be cut to study the bucco-lingual dimension, a repositioning system will have to be in place. Traditional pin systems work well, but are most often not available in the dental office. The author proposes a pinless system (Accu-trac, Coltene-Whaledent, Inc, New York, NY) that will allow the cast to be sectioned; the individual pieces can then be repo-



**Figure 19:** The PVS copy with guided sleeve positioned for rapid fabrication of additional H-frames.



**Figure 21:** Application of PVS adhesive.



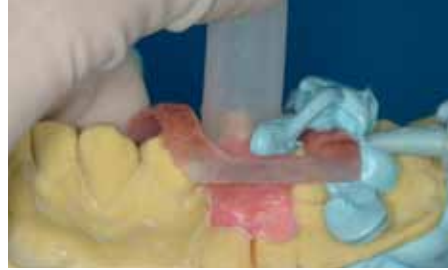**Figure 23:** Disposable impression tray positioned to aid in containing the stiff PVS bite registration material.

sitioned back into the base of the system and will be correctly interrelated spatially again. Once the impression is cast and the base is formed in the pinless tray system, the impression is removed and the cast is now ready for the transfer of the clinically acquired information. A local impression is made of the implant site, which will be used later in the process to reconstitute the gingival component.

The putty-staple assembly is positioned onto the cast, and the long axis of the staple is transferred to the cast as this is the approved mesio-distal position of the axis of the proposed implant (Figure 5). The cast is removed from the base and is sectioned with a large diamond disk (45 Mm, Xpdent Corporation, Miami, FL) exactly according to the marked long axis of the staple. Once cut, the tissue-depth information that was previously recorded is now transcribed to the cast. The dots are connected and the soft-tissue at the outside of the line can be marked. Consequently, the material inside



**Figure 20:** Individualization of standard H-frame.



**Figure 22:** Application of PVS bite registration material incorporating H-frame. Note the position of plastic tubing, which will facilitate exposing the guided sleeve.

of the line is the bone volume in a buccolingual direction.

The desired implant position from a buccolingual direction is marked on the cast, guided by the available bone and the requirements for the prosthetic reconstruction. The axis is also marked onto the crestal part of the cast, as this will guide the entry point of the drill bit during the cast osteotomy (Figure 6).

The position of the top of the implant is marked on the cast and this horizontal position is extended laterally onto the cast, because the cast osteotomy will obliterate the information in the position of the analog. This depth is governed by available bone volume and the emergence profile requirements for the prosthesis. Most often this will range from 2 mm to 3 mm from the marginal gingival contour as proposed for the definitive restoration.<sup>20</sup>

The mesio-distal plane is now represented by the surface created through the transverse cut cast, while the buccolingual axis has been transcribed onto the cast. First, the rotational component of these two planes has to be copied to a surveyor table. To do so, the Accu-trac tray (Accu-trac, Coltène-Whaledent, Inc, Cuyahoga Falls, OH) is fitted with the part of the cast that has been marked with the disto-lingual axis. The tray members are closed so that the sectional cast is correctly related to the base of the tray. The assembly is placed into a surveyor table. A drill bit in the size corresponding

with the analog size for the selected implant width is placed in a drill press (MicroLux®, MicroMark, Berkeley Heights, NJ). The surveyor table is positioned in the drill press. The press is lowered to place the drill bit at the level of the residual ridge on the sectioned cast (Figure 7). The surveyor table is unlocked and can now rotate freely in both x and y planes. The drill bit is placed flush with the transverse cut surface of the residual ridge to capture the mesio-distal plane and, while maintaining contact with said plane, the table is rotated to coincide with the marked axis of the buccolingual plane (Figure 8). The table is locked, and the angulations are rechecked (Figure 9). The surveyor table is now programmed with the rotation information for the x and y planes. The Accu-trac tray assembly is removed from the surveyor table; the remaining section of the cast is placed back into the tray, and the locking members are closed; this will have related the cast to its original configuration.

The Accu-trac tray assembly is now repositioned in the drill press. Because the rotational information for the model osteotomy is programmed in the surveyor table, the remaining translation component is set by moving the surveyor table under the tip of the drill bit, in the position that coincides with the marked crest and buccal cut. Once correct, the drill bit is lowered and a cast osteotomy is made, slightly deeper than the length of the analog combined with the soft tissue depth. All of the information needed to place the implant analog in the correct 3-D position in the cast is now available.

The cast is then removed from the Accu-trac tray and one of the sections is removed. An implant analog coinciding with the selected implant width is now placed into the semi-circular part of the previously made cast osteotomy, with the top of the analog coinciding with the previously marked line indicating the depth of the implant platform in relation to the buccal margin gingival level (Figure 10 through Figure 12). The analog is secured with cyano-acrylate glue (Zap-a-Gap, Pacer Technology, LLC, Rancho Cucamonga, CA). Once set, the exposed long axial part of the analog is coated with cyano-acrylate glue, and the remaining section of the cast is repositioned into the tray. The locking members are closed, and the glue is allowed to set. Upon setting a section above, the analog is removed to start the reconstitution of the gingival tissue. The previously made sectional impression is perforated at contra-lateral positions, placed



onto the cast and a heavy-body polyether impression material (Permadyne™ 3M ESPE, St. Paul, MN) is injected through one of the perforations. Excess material will flow through the vent hole, indicating complete fill of the defect. The polyether material is chemically dissimilar to the casting PVS, so it will not adhere. Upon setting, the soft tissue mask can be shaped to resemble the desired subgingival contour.

## THE SURGICAL GUIDE

The 3-D position of the future implant has now been established on the cast, and should now be copied to a transfer medium, so it can be used to place a dental implant in the clinically desired position.

Restrictive surgical guides traditionally have been made with an acrylic or a composite material. Both materials are inherently hard, and non-deformable. To correctly duplicate the information to the mouth, it is of the utmost importance that the guide fits the clinical supportive structure in a similar fashion as it does on the working cast. A small blemish on the cast will prevent the guide from seating clinically, hence the need to disclose hard surgical guides to adjust premature seating points and ensure correct seating. This author proposes the use of a stiff PVS bite registration material to fabricate the surgical guide. The PVS material will seat completely even if it encounters a slight discrepancy, and it will snap over the height of contour of the supporting teeth, adding to the retentive aspect of this type of surgical guide. In addition, its fabrication is rapid, relatively inexpensive, and can be executed in the dental office.

The PVS bite registration material is not strong enough to maintain a guided sleeve in position during surgery, so a supporting framework will have to be incorporated into the PVS surgical guide. In an earlier design of the PVS surgical guide, metal wires were welded to a guide sleeve to create a rigid framework<sup>20</sup> (Figure 13 through Figure 17).

An alternative will be proposed here. A guided sleeve consistent with the selected implant width (Nobel Biocare, Yorba Linda, CA) is incorporated into a light-polymerizing laboratory composite material (Triad Custom Tray Material, DENTSPLY International, Inc, York, PA) shaped in an H-configuration. The long leg of the H-frame is approximately 30 mm in length and 4 mm wide, the short leg of the H-frame is about 20 mm in width. The total height is approximately 3 mm. The guided sleeve is incorporated into the short leg of

the H-frame (Figure 18). Once one frame has been made, it can be copied with PVS impression material, and this duplicate can be used to quickly fabricate additional H-frames (Figure 19).

A laboratory implant guide pin is placed into the H-frame, and this assembly is secured to the analog on the cast. The H-frame is corrected as needed, so it will not touch any of the tissues on the cast, preventing incorrect seating and discrepancies. The composite material of the H-frame is merely required to hold the sleeve stable within the PVS bite registration material. Only PVS material will be in intimate contact with the supportive tissues. A few layers of aluminum foil will be used as a space maintainer when a thin, flowable laboratory composite (Triad Gel, DENTSPLY International, Inc, York, PA) is used to connect the open parts of the H-Frame (Figure 20). The composite parts are modified as needed to fit within the disposable impression tray that will be used later in the process. A PVS tray adhesive material is used to coat the H-frame (Figure 21) and a 20-mm piece of plastic tubing is placed over the extruding part of the laboratory-guided cylinder pin to prevent the overflow of PVS material onto the top of the guided sleeve (Figure 22). Therefore, when the guide is finished, the surface of the guided sleeve might not get accidentally damaged. Because the material of the guide is similar to the casting material, a Teflon separating medium is

applied (Release®, Cetylite Industries, Inc, Pennsauken, NJ). A sectional disposable impression tray is perforated, so it will fit over the tube/H-frame assembly and coated with a PVS adhesive. A stiff PVS material (Blu-Mousse®, Parkell Inc, Edgewood, NY) is injected under and around the H-frame and the impression tray is positioned over it to contain the PVS material (Figure 23). Upon setting, the plastic tube is removed and the laboratory implant guide pin is removed. Now the PVS guide can be released from the cast. The lateral walls next to the guide sleeve are removed to create access for the clinical instrumentation (Figure 24). The guide is placed intraorally and a periapical radiograph is taken to confirm the correctness of the trajectory of the guide by extending the walls of the surgical sleeve onto the implant site on the radiograph.

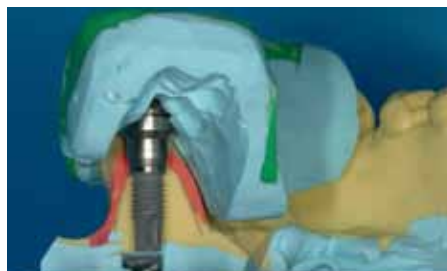Because the exact position of the implant is known before the surgical placement (Figure 25), if desired, the prosthetic final abutment and or provisional can be pre-made for immediate temporization (Figure 26 and Figure 27).

## CONCLUSION

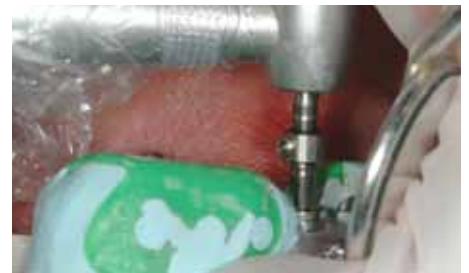Guided surgery allows for the precise placement of pre-planned dental implants, following a minimally invasive protocol, while allowing the possibility to continue with immediate temporization. This article described an analog method to guided implant placement, where the information acquired by bone sounding and periapical



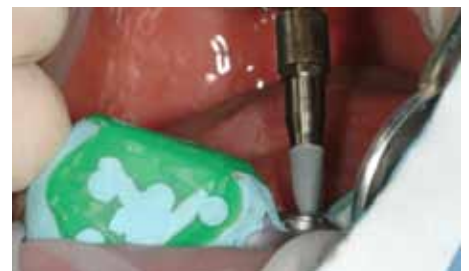**Figure 24:** Finished PVS surgical guide, with access for instrumentation to the guided sleeve. Note the relationship of the sleeve and the laboratory analog.



**Figure 25:** The PVS surgical guide with the dummy implant showing the interrelationship between guide and planning.



**Figure 26:** Clinical osteotomy guided by the surgical guide and depth-stop on the twist drill.



**Figure 27:** Dental implant readied for placement through the PVS surgical guide.

radiographs is transferred to a PVS cast. The position of the platform of the laboratory analog in the cast is transferred to a PVS surgical guide. This guide will allow for the exact placement of a dental implant in a very simple surgical procedure, because surgery is a mere execution of the plan encoded into the surgical guide. This technique will allow dentists with varying surgical skill levels to deliver exceptional care, all in a patient-friendly fashion.

## AUTHOR'S NOTE

Clinical videos demonstrating the surgical component of model-based guided implant placement are freely available on [www.youtube.com](http://www.youtube.com), keywords "Stumpel DDS."

## REFERENCES

1. ADA survey reveals increase in dental implants over five year period [news release]. Chicago, IL: American Dental Association; April 2002. [http://www.ada.org/public/media/releases/0204\\_release01.asp](http://www.ada.org/public/media/releases/0204_release01.asp).
2. Quinlan P, Richardson CR, Hall EE. A multipurpose template for implant placement. *Implant Dent*. 1998;7(2):113-121.
3. Mizrahi B, Thunthy KH, Finger I. Radiographic/surgical template incorporating metal telescopic tubes for accurate implant placement. *Pract Periodontics Aesthet Dent*. 1998;10(6):757-765.
4. Weinberg LA, Kruger B. Three-dimensional guidance system for implant insertion: Part I. *Implant Dent*. 1998;7(2):81-93.
5. Atsu SS. A surgical guide for dental implant placement in edentulous posterior regions. *J Prosthet Dent*. 2006;96(2):129-133.
6. Shotwell JL, Billy EJ, Wang HL, Oh TJ. Implant surgical guide fabrication for partially edentulous patients. *J Prosthet Dent*. 2005;93(3):294-297.
7. Meitner SW, Tallents RH. Surgical templates for prosthetically guided implant placement. *J Prosthet Dent*. 2004;92(6): 569-574.
8. Windhorn RJ. Fabrication and use of a simple implant placement guide. *J Prosthet Dent*. 2004;92(2):196-199.
9. Tsuchida F, Hosoi T, Imanaka M, Kobayashi K. A technique for making a diagnostic and surgical template. *J Prosthet Dent*. 2004; 91(4):395-397.
10. Saadoun AP, Touati B. Soft tissue recession around implants: is it still unavoidable?—Part I. *Pract Proced Aesthet Dent*. 2007; 19(1):55-62.
11. Traxler M, Ulm C, Solar P, Lill W. Sonographic measurement versus mapping for determination of residual ridge width. *J Prosthet Dent*. 1992;67(3):358-361.
12. Sümnick W. Determining the alveolar ridge width in planning treatment with endosseous implants [in German]. *Stomatol DDR*. 1990; 40(4):120-121.
13. Wilson DJ. Ridge mapping for determination of alveolar ridge width. *Int J Oral Maxillofac Implants*. 1989;4(1):41-43.
14. Allen F, Smith DG. An assessment of the accuracy of ridge-mapping in planning implant therapy for the anterior maxilla. *Clin Oral Implants Res*. 2000;11(1):34-38.
15. Flanagan D. A nonradiologic method for estimating bone volume for dental implant placement in the completely edentulous arch. *J Oral Implantol*. 2001;27(3):115-117.
16. Ten Bruggenkate CM, de Rijcke TB, Kraaijenhagen HA, Oosterbeek HS. Ridge mapping. *Implant Dent*. 1994;3(3):179-182.
17. Jisander S. A device for measuring bone thickness in relation to dental implants. *J Oral Maxillofac Surg*. 1996;54(10):1254-1255.
18. Davis WM. How an implant caliper can aid in planning dental implant restoration. *J Am Dent Assoc*. 1996;127(9):1377.
19. Perez LA, Brooks SL, Wang HL, Eber RM. Comparison of linear tomography and direct ridge mapping for the determination of edentulous ridge dimensions in human cadavers. *Oral Surg Oral Med Oral Pathol Oral Radiol Endod*. 2005;99(6):748-754.
20. Grunder U, Gracis S, Capelli M. Influence of the 3-D bone-to-implant relationship on esthetics. *Int J Periodontics Restorative Dent*. 2005;25(2):113-119.
21. Stumpel LJ. Cast-based guided implant placement: A novel technique. *J Prosthet Dent*. 2008;100:61-69.